

QP4 – Daily Question Preview: Day 4

Moderator: Roy Gulick, MD

IDBR
INFECTIOUS DISEASE BOARD REVIEW
AUGUST 20-24
2022

Daily Question Preview: Day 4

Moderator: Roy Gulick, MD

7/31/2022

INFECTIOUS DISEASE BOARD REVIEW **PREVIEW QUESTION**

4.1 An asymptomatic patient with a new diagnosis of HIV (CD4 = 10 cells/uL and HIV Viral Load 300,000 copies/uL is started on antiretroviral therapy (dolutegravir plus tenofovir alafenamide/emtricitabine).

His labs are unremarkable as is his chest xray.

His serum toxoplasma IgG is positive.

He asks whether you want to add prophylaxis for pneumocystis pneumonia but warns you that twice when he has taken sulfonamides he has developed hives and laryngeal edema.

INFECTIOUS DISEASE BOARD REVIEW **PREVIEW QUESTION**

4.1 What would you recommend regarding PCP and Toxo prophylaxis?

A) No chemoprophylaxis: his viral load should fall quickly, and his CD4 will rise quickly in response to this first exposure to antiretroviral therapy

B) Trimethoprim sulfamethoxazole plus solu-medrol dose pak

C) Dapsone

D) Aerosol pentamidine plus pyrimethamine

E) Atovaquone

INFECTIOUS DISEASE BOARD REVIEW **PREVIEW QUESTION**

4.2 The patient whose photo is shown is HIV positive (CD4=10 cells/uL, VL=2 mil copies) and has noted these lesions developing on his trunk, face and extremities over the past 8 months.

He has had low grade fevers for several months.

For your differential diagnosis, what besides Kaposi sarcoma would be the most likely cause of these lesions and their associated fever?

INFECTIOUS DISEASE BOARD REVIEW **PREVIEW QUESTION**

4.2



INFECTIOUS DISEASE BOARD REVIEW **PREVIEW QUESTION**

4.2 The most likely cause of these skin lesions, if they are not Kaposi sarcoma, is:

A) HHV-6

B) CMV

C) Cryptococcus neoformans

D) Bartonella

E) Rhodococcus

QP4 – Daily Question Preview: Day 4

Moderator: Roy Gulick, MD

INFECTIOUS DISEASE BOARD REVIEW PREVIEW QUESTION

4.3 A 43-year-old man with HIV has CD4 900-1200 and HIV RNA consistently <200 copies over the last 11 years.

Do you recommend starting ART?

A) Yes, all current guidelines recommend starting.
B) No, he's a long-term non-progressor and doesn't need ART.
C) No, he should wait until his viral load level is confirmed >200 copies/ml.
D) No, he should wait until CD4 is confirmed <500 cells/uL.

INFECTIOUS DISEASE BOARD REVIEW PREVIEW QUESTION

4.4 You have been monitoring a 36-year-old man with HIV, CD4 ~350, VL 636,000 who is now ready to start ART, but wants the "simplest regimen possible."

Which of these regimens do you recommend?

A) IM cabotegravir/rilpivirine
B) tenofovir alafenamide/emtricitabine/rilpivirine
C) abacavir/lamivudine + efavirenz
D) dolutegravir/lamivudine
E) tenofovir alafenamide/emtricitabine/bictegravir

INFECTIOUS DISEASE BOARD REVIEW PREVIEW QUESTION

4.5 25-year-old man presents with newly diagnosed HIV. Had an episode c/w acute seroconversion syndrome 4 months ago.

Initial HIV RNA 40,000; CD4 443 cells/uL.

He wants to start ARV therapy.

INFECTIOUS DISEASE BOARD REVIEW PREVIEW QUESTION

4.5 A baseline genotype is ordered that shows an M184V mutation.

Which of the following drugs will have reduced susceptibility with this mutation?

A) Efavirenz
B) Zidovudine
C) Tenofovir
D) Etravirine
E) Emtricitabine

INFECTIOUS DISEASE BOARD REVIEW PREVIEW QUESTION

4.6 34 yo woman diagnosed with HIV 10 years ago. Initially presented with PJP.

Initial Lab values

- CD4 82 cells/uL
- VL 106,000 c/mL

Started on TDF / FTC / EFV (FDC). Did well for a while, then the regimen failed.

INFECTIOUS DISEASE BOARD REVIEW PREVIEW QUESTION

4.6 The genotype shows an M184V and K65R mutations.

Which nRTI drugs would you include?

A) ZDV
B) TDF
C) ddI
D) ABC

QP4 – Daily Question Preview: Day 4

Moderator: Roy Gulick, MD

INFECTIOUS DISEASE BOARD REVIEW PREVIEW QUESTION

4.7 A 22-year-old man presents with fever, mouth pain, and skin rash.

PE reveals 3 small oral ulcers and diffuse macular rash.

Labs show WBC 3K, platelets 89K, monospot negative, RPR NR, HIV antibody negative, HIV RNA 1,876,000 cps/ml.

INFECTIOUS DISEASE BOARD REVIEW PREVIEW QUESTION

4.7 Which statement is correct?

A) ART should not be offered.

B) ART would decrease his symptoms.

C) ART has long-term virologic benefits in this setting.

D) ART has long-term clinical benefits in this setting.

INFECTIOUS DISEASE BOARD REVIEW PREVIEW QUESTION

4.8 Sweet Syndrome is *most* likely to occur in a patient with which of the following illnesses?

A) Ulcerative colitis

B) Adult-onset Still's Disease

C) Acute leukemia

D) Systemic lupus

E) Ankylosing spondylitis

INFECTIOUS DISEASE BOARD REVIEW PREVIEW QUESTION

4.9 38 y/o M physician, previously healthy, with periodic travel to South Africa for medical research work.

Reports a positive TST six years ago, and admits poor adherence with a course of isoniazid preventive therapy at that time.

Now with 5 weeks of fever, chills, night sweats, 10-lb wt loss, productive cough. CXR shows RUL cavitory lesion.

Sputum GeneXpert MTB/RIF test result is "MTB detected" and "Rifampin resistance not detected" (culture results pending).

HIV test is negative, liver chemistries are normal.

INFECTIOUS DISEASE BOARD REVIEW PREVIEW QUESTION

4.9 What is the best course of action?

A) Prescribe 9 months of isoniazid for presumed latent TB infection

B) Do nothing pending culture results

C) Start TB treatment with rifampin, isoniazid, PZA, ethambutol

D) Start TB treatment with rifampin, isoniazid, PZA

E) Start TB treatment with a regimen for multidrug-resistant TB

INFECTIOUS DISEASE BOARD REVIEW PREVIEW QUESTION

4.10 24 y/o M from Zambia, in U.S. for community college, recently tested HIV-positive with CD4 400, not yet on ART.

He has a prominent anterior cervical lymph node but is otherwise well-appearing with normal BMI, normal liver and renal chemistries, and mild anemia.

Lymph node biopsy grows *M. tuberculosis* in culture.

QP4 – Daily Question Preview: Day 4

Moderator: Roy Gulick, MD

INFECTIOUS DISEASE BOARD REVIEW PREVIEW QUESTION

4.10 What is the best course of action with respect to the timing of TB therapy and HIV therapy?

- A) Start ART immediately, defer TB tx
- B) Start TB tx immediately, defer ART until after completion of 6 months of TB tx
- C) Start TB tx immediately, and start ART within about 8 weeks
- D) Start both TB tx AND ART immediately

INFECTIOUS DISEASE BOARD REVIEW PREVIEW QUESTION

4.11 55-year-old man presents with R hip pain. H/o COPD requiring steroids frequently.

HIV diagnosed 17 years ago. On TDF / FTC / EFV for 10 years; originally on IND / AZT / 3TC.

Initial HIV RNA 340,000; CD4 43 cells/ul
▪ Now HIV RNA < 50 c/ml; CD4 385 cells/ul

Electrolytes NL; Creat 1.3; Phos 3.5 Ca 8.5. Mg 2.1, alk phos 130; U/A neg.

R Hip film unremarkable.

INFECTIOUS DISEASE BOARD REVIEW PREVIEW QUESTION

4.11 Which if the following is the most likely underlying cause of his hip pain?

- A) Osteonecrosis of Femoral Head
- B) Fanconi's syndrome
- C) Vitamin D deficiency
- D) Tenofovir bone disease
- E) Hypogonadism

INFECTIOUS DISEASE BOARD REVIEW PREVIEW QUESTION

4.12 46yowf c/o (CD4 582, VL <50 c/ml) c/o 1 week cramps in calves, tingling in hands, feet.

Today awoke and can't move except hands/feet.

No F/C, chest pain, SOB, incontinence.

+ chronic diarrhea 4x/day.

Chronic fatigue, poor appetite.

Meds

- TDF/FTC/EFV (2008), on TDF/FTC/Elv/cobi since 2014
- zoloft, bupropion, norco, prilosec, trazodone, pravachol, ibuprofen

INFECTIOUS DISEASE BOARD REVIEW PREVIEW QUESTION

4.12 VS: T 98.2 P 79 BP 112/73
RR 16, O2 sat 97%

Pertinent findings:

- Neuro: CNII-XII intact, strength 1+ all extremities except 4+ hand/wrist and ankles.
- NI reflexes. Alert, oriented.
- Labs

137 116 5	Gluc 83	
1.6 18 1.0	AG 3	
Ca 8.3	Phos 1.8	Mg 2.1
Lactate 1.5	CK 186	
UDS +cocaine/benzo/plate		
UA: 1.015	pH 6.5	2+ pro
	Neg:	gluc/ketones

INFECTIOUS DISEASE BOARD REVIEW PREVIEW QUESTION

4.12 Which of the following is the most likely diagnosis?

- A) Cocaine toxicity
- B) Nucleoside-induced myopathy (ragged red fiber disease)
- C) Serotonin Syndrome
- D) Statin toxicity
- E) Fanconi's syndrome

QP4 – Daily Question Preview: Day 4

Moderator: Roy Gulick, MD

INFECTIOUS DISEASE BOARD REVIEW PREVIEW QUESTION

4.13 A 45-year-old international agricultural researcher presents in June in the US with fever, cough, diarrhea, myalgia, sore throat, and dyspnea. He is hypotensive and hypoxemic.

CBC shows mild leukopenia, chemistry panel and LFT's are normal.

Three days prior to the onset of his illness he was inspecting poultry operations Jiangsu Province, China.

INFECTIOUS DISEASE BOARD REVIEW PREVIEW QUESTION

4.13 Assuming the he acquired his severe respiratory illness from the poultry he was inspecting, the most likely diagnosis would be:

- A) H1N1 influenza
- B) H3N2 influenza
- C) Leptospirosis
- D) H7N9 influenza
- E) Blastomycosis

INFECTIOUS DISEASE BOARD REVIEW PREVIEW QUESTION

4.14 38yo female with 1 day of sore throat and fever.


Childhood history of anaphylaxis to penicillin.

Physical exam

- T=102.3
- HEENT-tonsillar purulence
- Neck-Tender bilateral anterior LAN

Labs:

- Rapid strep antigen test negative



INFECTIOUS DISEASE BOARD REVIEW PREVIEW QUESTION

4.14 What is the most appropriate antimicrobial treatment?

- A) Cephalexin
- B) None
- C) Doxycycline
- D) Clindamycin
- E) Levofloxacin

INFECTIOUS DISEASE BOARD REVIEW PREVIEW QUESTION

4.15 A 32-year-old woman is seen for a bad sore throat for 4 days.

Recently returned from her sister's wedding in Kazakhstan.

She c/o odynophagia, and a low-grade fever. Today, she noted a choking sensation, prompting medical evaluation.

INFECTIOUS DISEASE BOARD REVIEW PREVIEW QUESTION

4.15 A 32-year-old woman is seen for a bad sore throat for 4 days. Recently returned from her sister's wedding in Kazakhstan.


She c/o odynophagia, and a low-grade fever. Today, she noted a choking sensation, prompting medical evaluation.

T 100.2F; P 126; BP 118/74.

HEENT: Submandibular swelling with gray exudate coating posterior pharynx.

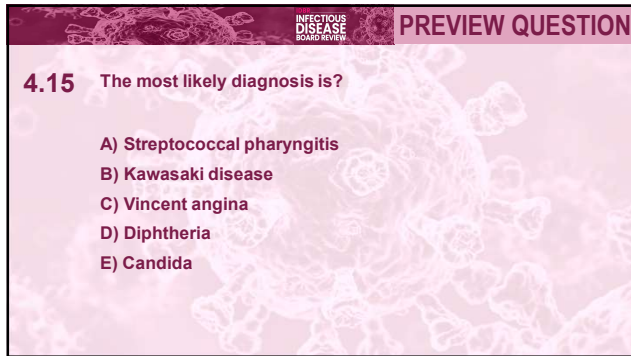
An S3 gallop is heard.

EKG shows 1st degree AV nodal block, QT prolongation, and ST-T wave changes.



QP4 – Daily Question Preview: Day 4

Moderator: Roy Gulick, MD



INFECTIOUS DISEASE BOARD REVIEW **PREVIEW QUESTION**

4.15 The most likely diagnosis is?

- A) Streptococcal pharyngitis
- B) Kawasaki disease
- C) Vincent angina
- D) Diphtheria
- E) Candida